



## ■ UPPER LIMB

# Anatomical variations of the deltoid artery

## RELEVANCE TO THE DELTOPECTORAL APPROACH TO THE SHOULDER

T. D. Bunker,  
T. D. A. Cosker,  
S. Dunkerley,  
J. Kitson,  
C. D. Smith

*From Royal Devon  
and Exeter Hospital,  
Exeter, United  
Kingdom*

**Despite the expansion of arthroscopic surgery of the shoulder, the open deltopectoral approach to the shoulder is still frequently used, for example in fracture fixation and shoulder replacement. However, it is sometimes accompanied by unexpected bleeding. The cephalic vein is the landmark for the deltopectoral interval, yet its intimate relationship with the deltoid artery, and the anatomical variations in that structure, have not previously been documented.**

**In this study the vascular anatomy encountered during 100 consecutive elective deltopectoral approaches was recorded and the common variants described. Two common variants of the deltoid artery were encountered. In type I (71%) it crosses the interval and tunnels into the deltoid muscle without encountering the cephalic vein. However, in type II (21%) it crosses the interval, reaches the cephalic vein and then runs down, medial to and behind it, giving off several small arterial branches that return back across the interval to the pectoralis major. Several minor variations were also seen (8%).**

**These variations in the deltoid artery have not previously been described and may lead to confusion and unexpected bleeding during this standard anterior surgical approach to the shoulder.**

**Cite this article: *Bone Joint J* 2013;95-B:657–9.**

The deltopectoral approach is the standard exposure used for many operations on the shoulder. It lies in the interneural plane between the axillary and musculocutaneous nerves and is easy to extend.<sup>1</sup>

There are only three major structures that cross the interval between deltoid and pectoralis major: the cephalic vein, the deltoid artery and the acromial artery. However, in 21% of cases smaller blood vessels cross the interval, 1 cm to 5 cm below the coracoid process, and these are often thought to be tributaries of the cephalic vein.<sup>2</sup>

The aim of this study was to document the anatomical variations of the cephalic vein and the deltoid artery so that the surgeon can anticipate variations, prevent bleeding and extend the approach with safety.

### Patients and Methods

Over a period of 18 months (January 2011 to June 2012) a prospective observational study was made on 100 consecutive patients undergoing a deltopectoral approach to the shoulder. The inclusion criterion was any patient aged > 18 years undergoing this approach. Exclusion criteria were revision surgery, acute fracture surgery (because there is often a large haematoma) and previous local radiotherapy.

A standardised approach was used with the patient in the supine position and the table in 10° of head-up tilt. The skin incision was made between the coracoid superiorly and just lateral to the axillary crease distally. For each patient the presence or absence of the cephalic vein was documented. The vein was protected and remained attached to the deltoid muscle laterally. The interval between the deltoid and pectoralis major was opened and the branches of the common trunk of the deltoid and acromial arteries were exposed by careful dissection. Any variations in the pattern of the acromial, deltoid and recurrent pectoral branches were recorded, and their relationships to the deltoid muscle and the cephalic vein.

### Results

The mean age of the patients was 65 years (SD 17; 23 to 87); 51 were women and 49 men. The right shoulder was operated on in 54 patients and the left shoulder in 46. The indications for surgery are shown in Table I.

There were four broad groups of anatomical variations. Type 1 was the most common, occurring in 71% of patients (Fig. 1). In this pattern the deltoacromial artery trifurcated into two major vessels, the deltoid artery and a

■ T. D. Bunker, FRCS, MD, Orthopaedic Surgeon  
■ T. D. A. Cosker, FRCS(Tr & Orth), MSc, Shoulder Fellow  
■ S. Dunkerley, MA(Oxon), MRCS, Orthopaedic Registrar  
■ J. Kitson, FRCS(Tr & Orth), BSc, Orthopaedic Surgeon  
■ C. D. Smith, FRCS(Tr & Orth), MD, MSc, Orthopaedic Surgeon  
Royal Devon and Exeter Hospital, Shoulder & Elbow Unit, Barrack Road, Exeter, Devon EX2 5DW, UK.

Correspondence should be sent to Mr C. D. Smith; e-mail: christophersmith3@nhs.net

©2013 The British Editorial Society of Bone & Joint Surgery  
doi:10.1302/0301-620X.95B5.31408 \$2.00

*Bone Joint J*  
2013;95-B:657–9.

Received 3 December 2012;  
Accepted after revision 23  
January 2013

**Table I.** Operations performed

| Procedure                       | n (%) |
|---------------------------------|-------|
| Anatomical shoulder replacement | 52    |
| Reverse shoulder replacement    | 26    |
| Open anterior stabilisation     | 13    |
| Subscapularis repair            | 7     |
| Hemiarthroplasty                | 1     |
| Open HAGL* repair               | 1     |
| Total                           | 100   |

\* HAGL, humeral avulsion glenohumeral ligament

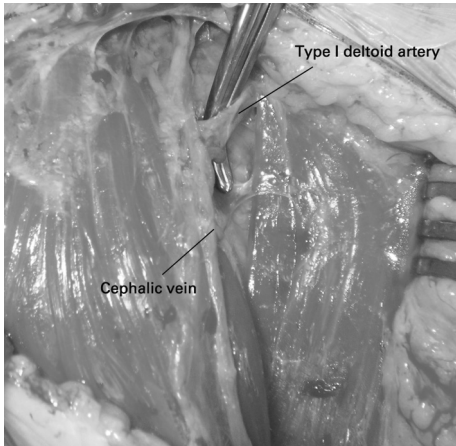


Fig. 1a

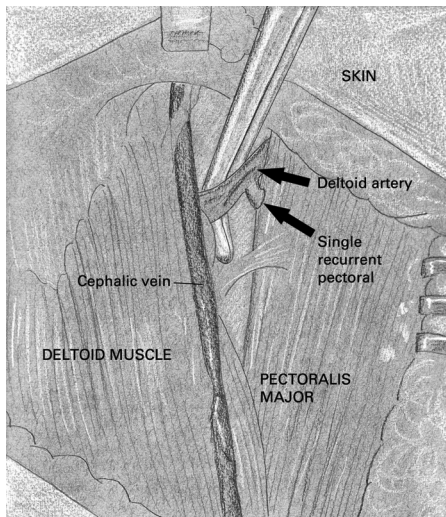


Fig. 1b

Intra-operative photograph (a) and diagram (b) of the type I pattern of the deltoid artery and recurrent pectoral branch.

recurrent pectoral branch, and one smaller vessel, an acromial artery. The deltoid artery crossed the interval towards but not as far as the cephalic vein, always entering the deltoid muscle between 5 mm and 7 mm medial and deep to the cephalic vein. The recurrent pectoral branch turned back on itself to enter the pectoralis major directly. The




Fig. 2a

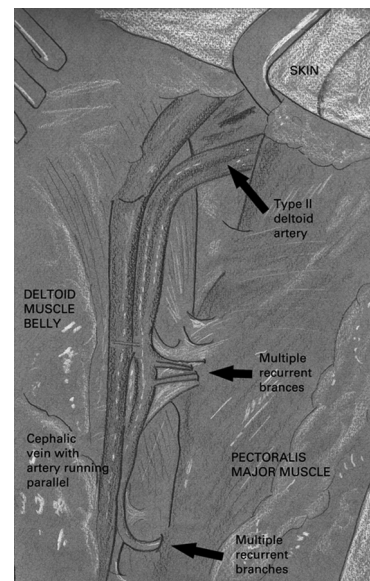


Fig. 2b

Intra-operative photograph (a) and diagram (b) of the type II pattern of the deltoid artery and recurrent pectoral branch.

acromial branch passed under the cephalic vein, where the vein crosses the interval proximally from lateral to medial, towards the anterior border of the clavicle, to run laterally adjacent to the acromioclavicular joint and the anterior acromion, in the plane between the coracoacromial ligament and the deltoid insertion.

Type II occurred in 21% of patients and was the most interesting variation, the one that has historically led to confusion (Fig. 2). In this pattern the deltoacromial artery bifurcated into a large deltoid artery and a small acromial

branch. The deltoid artery crossed the deltopectoral interval and came to lie on the deltoid adjacent to the cephalic vein. It then passed down the arm, lying deep and medial to the cephalic vein and giving off branches to the deltoid muscle. However, it also gave off between two to five fourth-generation vessels that re-crossed the deltopectoral interval to enter the pectoralis major. The acromial branch behaved exactly as in type I.

Type III occurred in 4% of patients and comprised a double deltoid artery. In this pattern the deltoacromial artery trifurcated, as in type I, but then the deltoid artery bifurcated to become a duplicated vessel.

Type IV pattern occurred in 2% of patients, in whom the deltoid artery was absent.

The cephalic vein was absent in 10% of patients and an accessory cephalic vein was present in 2%.

## Discussion

The deltoid artery has classically been described as arising as one of the four branches of the thoraco-acromial trunk from the front of the second part of the axillary artery. It crosses the top of the deltopectoral interval from medial to lateral, to run with the cephalic vein giving small branches to both deltoid and pectoralis major muscles.<sup>3</sup> Previous studies have looked at the variations in the origin of the thoraco-acromial trunk from the second part of the axillary artery,<sup>2</sup> perfusion of the pectoralis major myocutaneous flap,<sup>4,5</sup> and perfusion of the deltoid muscle.<sup>6</sup> However, there have been no studies looking at the variations of the deltoid artery and recurrent pectoral artery in relation to the deltopectoral approach and the cephalic vein. We have identified and classified the major variations and related them to this surgical approach.

The deltoid artery has two common variations, with the predominant variation (type I, 71%) crossing the interval and giving off a single large recurrent pectoral branch as it does so. The deltoid artery tunnels into the muscle belly of deltoid without encountering the cephalic vein. Extending the approach superiorly will require ligation of this single deltoid artery.

The second common variant (type II, 21%) is the most interesting and may cause confusion to surgeons unfamiliar with this approach. In this variant the deltoid artery passes across the interval without giving off a recurrent pectoral branch. The artery comes to lie on the surface of the deltoid muscle adjacent to, and intimately related to, the cephalic vein. Because it lies medial to and behind the cephalic vein, and can appear small in relation to the vein, it is commonly overlooked. In this variation the artery gives off many small branches that re-cross the interval to supply pectoralis major. This can cause confusion. These small arteries might be mistaken for tributaries of the cephalic vein, which thus might be dissected from its bed and displaced medial to the plane of dissection, leading to an increase in bleeding during and after the procedure. This can be avoided by coagulating the small arterial branches that re-cross the interval into pectoralis major individually and leaving the cephalic vein undisturbed.

In conclusion, we have identified and classified variations in the anatomy of the deltoid artery, and their relationships to the cephalic vein, the primary landmark for the deltopectoral approach. This knowledge will help surgeons avoid unnecessary bleeding when using this approach in operations on the shoulder.

No benefits in any form have been received or will be received from a commercial party related directly or indirectly to the subject of this article.

This article was primary edited by P. Baird and first-proof edited by J. Scott.

## References

1. Hoppenfeld S, deBoer P, Buckley R. The shoulder. In: *Surgical exposures in orthopedics: the anatomic approach*. Fourth ed. Philadelphia: Lippincott Williams & Wilkins, 2009:1–65.
2. Pandey SK, Shukla VK. Anatomical variations in the origin and course of the thoracoacromial trunk and its branches. *Nepal Med Col J* 2004;6:88–91.
3. Standring S, ed. *Gray's anatomy: the anatomical basis for clinical practice*. 40th ed. Philadelphia: Churchill Livingstone Elsevier, 2008.
4. Freeman JL, Walker EP, Wilson JS, Shaw HJ. The vascular anatomy of the pectoralis major myocutaneous flap. *Br J Plast Surg* 1981;34:3–10.
5. Yang D, Marshall G, Morris SF. Variability of vascularity of the pectoralis major muscle. *J Otolaryngol* 2003;32:12–15.
6. Hue E, Gagey O, Mestdagh H, et al. The blood supply of the deltoid muscle: application to deltoid flap techniques. *Surg Radiol Anat* 1998;20:161–165.