

# Shoulder & Elbow

<http://sel.sagepub.com/>

---

## **Capstan screw rotator cuff repair: a novel two-row mini-open technique**

Paul Guyver, Alex Goubran, Aishling Jaques, Christopher Smith and Tim Bunker

*Shoulder & Elbow* 2014 6: 171 originally published online 6 May 2014

DOI: 10.1177/1758573214532910

The online version of this article can be found at:

<http://sel.sagepub.com/content/6/3/171>

---

Published by:



<http://www.sagepublications.com>

On behalf of:

[British Elbow & Shoulder Society](#)

**Additional services and information for *Shoulder & Elbow* can be found at:**

**Email Alerts:** <http://sel.sagepub.com/cgi/alerts>

**Subscriptions:** <http://sel.sagepub.com/subscriptions>

**Reprints:** <http://www.sagepub.com/journalsReprints.nav>

**Permissions:** <http://www.sagepub.com/journalsPermissions.nav>

>> [Version of Record](#) - Jun 17, 2014

[OnlineFirst Version of Record](#) - May 6, 2014

[What is This?](#)

# Capstan screw rotator cuff repair: a novel two-row mini-open technique

Paul Guyver<sup>1</sup>, Alex Goubran<sup>1</sup>, Aishling Jaques<sup>1</sup>,  
Christopher Smith<sup>1</sup> and Tim Bunker<sup>2</sup>

Shoulder & Elbow  
2014, Vol. 6(3) 171–177  
© The Author(s) 2014  
Reprints and permissions:  
sagepub.co.uk/journalsPermissions.nav  
DOI: 10.1177/1758573214532910  
sel.sagepub.com



## Abstract

**Background:** Prospective data collection occurred between 2000 and 2010 on 143 consecutive patients with symptomatic rotator cuff tears, aiming to examine the end-result of a new technique of mini-open double row repair: the Capstan screw technique.

**Methods:** All patients had a pre- and postoperative Oxford Shoulder Score (OSS), American Shoulder and Elbow Surgeons (ASES) score and range of movement measurements. All were followed up for a minimum of 1 year with an exit questionnaire. Subscapularis repairs, small (<1 cm) and massive (>5 cm) supraspinatus repairs were excluded. Ninety-nine patients fitted the inclusion and exclusion criteria of whom 87 had a complete data set.

**Results:** The mean (SD) pre-operative OSS was 21.85 (8.6) and the mean (SD) postoperative OSS was 44.58 (5.2) ( $p < 0.0001$ ). The mean (SD) pre-operative ASES score was 51.5 (19.4) and the mean (SD) postoperative ASES score was 86.42 (17.06) ( $p < 0.0001$ ). Flexion improved from a mean of 119° to 170° ( $p < 0.0001$ ). The clinical re-tear rate was 3.4% and the imaged re-tear rate was 6.8%. In total, 91% of patients were satisfied with the procedure. There were no deep infections and two (2%) minor wound infections. There was no single instance of deltoid dysfunction.

**Conclusions:** The Capstan screw technique represents a simple, rapid, strong and reliable mini-open technique.

## Keywords

Capstan screw, mini-open, moderate and large tears, rotator cuff repair

Date received: 2nd December 2013; accepted: 18th March 2014

## Introduction

Over the last 10 years, the number of rotator cuff repairs performed in the UK has increased from 1,357 to 8,735, representing an increase of 544%.<sup>1</sup> Five years ago, it was reported that UK surgeons were performing 40% of all rotator cuff repairs (RCRs) open or mini-open, 47% total arthroscopic and 13% both.<sup>2</sup>

The last decade has seen a shift from open RCR to arthroscopic cuff repair. Patients want minimally invasive surgery, less collateral damage, a shorter hospital stay and minimal postoperative pain. However, numerous studies show that the functional outcome scores show no benefit either way.<sup>3</sup> Although it is often assumed that postoperative pain is less following arthroscopic surgery, a recent prospective controlled study shows that there is no significant difference in postoperative pain related to surgical approach (arthroscopic or open).<sup>4</sup> There is no doubt that arthroscopic

repair remains more time consuming (113 minutes versus 103 minutes)<sup>5</sup> than open repair. The Capstan screw repair had a mean surgical time of less than 60 minutes.

The objective of rotator cuff repair is to create a strong repair that remains structurally intact for a decade with a low re-tear rate. The re-tear rates for arthroscopic rotator cuff repairs have presently been reported as high. Studies show a cluster at 20% to 30% re-tear rate;<sup>6–11</sup> there is then a cluster at a 50% to 80% re-tear rate,<sup>12–17</sup> with all of these being in tears more than 3 cm in size. Open repairs have a re-tear rate

<sup>1</sup>Royal Devon and Exeter Hospital, Exeter, UK

<sup>2</sup>Thirlby Cottage, Kenn, Exeter, UK

### Corresponding author:

Paul M Guyver, Royal Devon and Exeter Hospital, Barrack Road, Exeter EX2 5DW, UK. Tel.: +07808298833.

Email: paul.guyver@nhs.net

of 13% to 31%, with moderate to large tears.<sup>7,15,16</sup> Previous studies have reported no significant difference in terms of the clinical and functional outcomes between intact ‘healed’ cuffs compared to re-tears.<sup>7,18–20</sup> However other studies state that the structural integrity of repaired rotator cuffs is strongly correlated to strength, endurance and range of motion,<sup>9,21–23</sup> thus concluding that re-tears should be considered as failures.

The Capstan screw technique was developed to create a stronger repair than the standard two-row anchor techniques aiming to allow rapid rehabilitation and also a low re-tear rate. The present prospective study aimed to document the change in patient-reported and clinician-reported outcome measures before and after surgery, and also to document the clinical and radiological re-tear rate following repair. This was achieved by using the Oxford Shoulder Score (OSS), American Shoulder and Elbow Surgeons (ASES) score, targeted ultrasound and magnetic resonance imaging (MRI) examination, range of movement, and a patient satisfaction questionnaire.

## Materials and methods

### Surgical technique

The novelty of this technique is that the medial row has standard anchors, although the lateral row takes all of the load of the cuff to a single, 6.5-mm diameter, 35-mm long screw with a low profile head (Arthrex, Naples, FL, USA).<sup>24</sup> This sits in strong cortical bone, 2 cm down the lateral shaft of the humerus, to which any number of sutures can be attached. The medial row sutures, having sealed off the medial footprint, are then taken as suture bridges to the Capstan screw. Typically, the screw will support sixteen suture tails. Acknowledging that the tendon suture interface is now the weakest part of the cuff repair, this technique allows multiple suture passes through the tendon to spread the load over as wide an area of the tendon as possible, typically twenty-four suture passes and eight suture bridges, leading to a reliable repair (Figures 1–4). The bone for the anchors was prepared in a standard way with minimal debridement to expose bleeding cancellous bone. The Capstan screw was tapped into the cortical bone and then screwed into position. Because it is inserted distal to the lateral edge of the footprint, the bone did not need to be prepared.

One hundred and forty-three consecutive patients undergoing rotator cuff surgery were included in the study between 2000 and 2010. All patients were asked to complete a pre-operative Oxford Shoulder Score (OSS), American Shoulder and Elbow Surgeons (ASES) score, range of movement measurements and

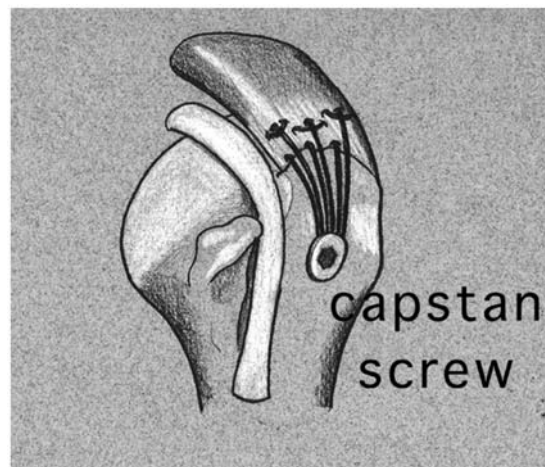


Figure 1. The Capstan screw technique.

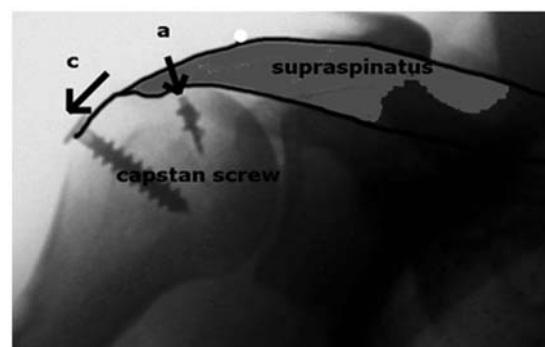


Figure 2. Radiograph illustrating the Capstan screw technique.


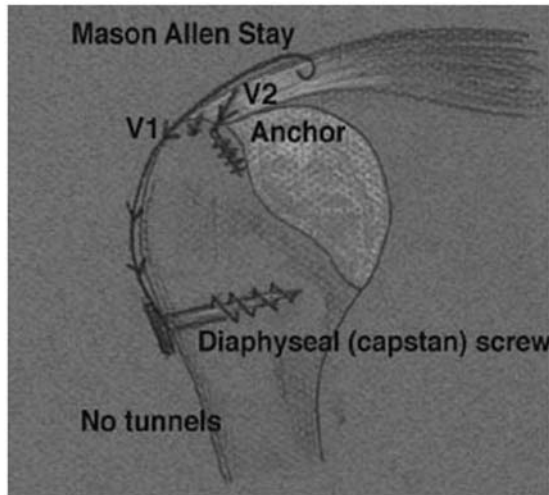


Figure 3. Capstan screw and suture bridges configuration.



**Figure 4.** Capstan screw force vectors.

were followed up for a minimum of 1 year with an exit OSS, ASES score and questionnaire. Subscapularis repairs, small repairs (<1 cm) and massive repairs (>5 cm) of supraspinatus were excluded.<sup>25</sup> Ninety-nine patients were found to have tears between 2 to 5 cm of whom 87 had full documentation, adequate follow-up and a completed final questionnaire.

The method of investigation and pre-operative procedures were noted. At surgery, tears were classified as moderate (1 cm to 3 cm) to large (3 cm to 5 cm)<sup>25</sup> and the shape, mobility and quality of tissue were documented. The suture pattern, number of sutures, number of medial anchors and number of suture bridges were also noted. Extra procedures (such as biceps tenotomy and acromioclavicular joint excision) and complications were recorded.

A clinical failure of the rotator cuff was defined as continued objective weakness and pain at a minimum 9 months postoperatively as reported by the patient. These patients underwent ultrasound examination to assess the integrity of the cuff repair.

The questionnaire that accompanied the OSS/ASES score at final review asked whether the patient felt that the treatment had been a success; would they recommend it to a friend; how quickly was the pain relieved; how soon after the operation could they sleep through the night, return to work and return to driving; contralateral symptoms; strength in reach; and smoking habits. Strength was tested by using sustained reach with a full 1-L bottle of water in a carrying bag, the arm in 90° of elevation and the elbow fully extended, as a surrogate for formal strength testing. Range of motion measurements were recorded by the patients through their pre- and postoperative questionnaires. The questionnaire provided a visual guide with various options of end range of movement for different planes.

Funding was achieved to conduct targeted ultrasound on two groups of 10 randomly selected patients. Ten 'asymptomatic' patients were selected from a group of patients who could sustain reach with the 1-L carrier bag test and 10 from the 'weak' group who could not sustain a 1-kg weight. Funding was attained for further targeted MRI to confirm re-tears after ultrasound examination.

Statistical analysis was predominantly with an unpaired Student *t*-test with two-way analysis of variance. Correlation between data sets was analyzed using Pearson's correlation coefficient. Frequency data were analyzed using a 2 × 2 contingency square table and tested with Pearson's uncorrected test. Statistical significance was set at  $\alpha = 0.05$ .

## Results

The mean (SD) age of the patients undergoing cuff repair was 59 (8.9) years and 66% were male. Sixty-one percent of operations were performed on the right shoulder. The follow-up was a minimum of 1 year and a mean of 43 months. Seventy percent of patients were treated with at least one cortisone injection prior to surgery. One patient was referred from another institution, having undergone a previous arthroscopic subacromial decompression. The diagnosis was initially made clinically in all patients and confirmed by ultrasound in 93% of patients, by MRI in 21% of patients, and by both ultrasound and MRI in 14% of patients.

Sixty-eight (78%) of the tears were moderate and 19 (22%) were large-sized tears. Forty-two percent were U-shaped tears, 38% were crescent shaped, 12% were L-shaped and 8% did not fit a discrete shape. Fourteen percent of the tears were relatively immobile and required more than a standard bursal and articular-sided release. These required either a rhomboid flap or junctional scar release.<sup>26,27</sup> Five patients (6%) were noted to have a very angiogenic appearance, similar to primary frozen shoulder, and three of these went on to develop stiffness postoperatively.

Nineteen (22%) patients had a biceps tenotomy at the time of cuff repair, eight (9%) had an acromioclavicular joint excision and one had a concurrent superior labral tear anterior to posterior repair.

All had a two-row Capstan screw repair. Most had two anchors to the medial row (70%) and 30% had one. Eighty-five percent had Mason Allen sutures, with most (75%) having either three or four Mason Allen sutures (13% with >4 sutures and 12% with <3 sutures).

Thirty-nine percent of patients had additional side-to-side sutures repair for L- or U-shaped tears. The mean (SD) number of suture passes through the

tendon was 20 (6.6) per patient, with a mean (SD) of 13 (4.4) suture bridges in addition per patient.

In 15% of patients, the quality of the tissue was deemed to be poor. The mean improvement in the OSS was greater in those patients with good quality tissue 23.3 compared to those with poor quality tissue 19.9, although this was not statistically significant ( $p = 0.26$ ).

The mean (SD) pre-operative OSS was 21.9 (8.6) and the mean (SD) postoperative OSS was 44.6 (5.2), which was significant ( $p < .0001$ ). The mean pre-operative ASES score was 51.5 (19.4) and the mean postoperative ASES score was 86.42 (17.06) ( $p < 0.0001$ ). Flexion improved from a mean (SD) of 119° (48°) to 170° (18°) ( $p < 0.0001$ ).

The clinical re-tear rate was 3.4% (3/87). Pre- and postoperative OSS for the three clinical re-tears were 23–30, 30–46 and 26–42, with pre- and postoperative ASES scores being 23–83, 43–86 and 48–90, respectively. Despite some of the scores suggesting a good outcome, all three patients complained of continued weakness with lack of endurance at follow-up. Ultrasound assessment of all of these patients confirmed a failure of the repair but all declined further surgery. The patients declined surgery on the basis that their symptoms did not merit further surgery, although it was offered. This left 84 of 87 patients who were clinically healed. Of these, 10 were weak in reach and the remaining 74 were strong in reach. We decided that the weak patients must have imaging to determine whether the cuff was structurally intact. An independent and highly experienced consultant musculoskeletal sonographer performed ultrasound scans and three were shown to have a re-tear, although seven were intact. Previous studies have all shown that strength was related to an intact cuff, although we considered that it was important to take a random selection of 10 clinically healed strong tears to ensure that these cuffs were intact. Ultrasound determined that seven were intact, although three were inconclusive; these three patients therefore had an MRI scan performed and all had intact cuffs on MRI. Thus the imaged re-tear rate was six of 87 patients (6.8%). Ninety-one percent of patients stated that their treatment had been successful and 94% said they would recommend it to a friend.

The re-tear group was composed of mostly moderate size (5/6) and U-shaped tears (4/6). Only one required a junctional release and none were deemed to have poor quality tissue at their index procedure. The mean pre- and postoperative OSS and ASES scores for this group were 26–38 and 43–80, respectively. The mean number of sutures passed and bridges were only two passes and one bridge higher in the re-tear group compared to the rest of the cohort (Table 1).

**Table 1.** Re-tears data.

Patient	Size of tear	Shape of tear	Number of sutures	Number of sutures bridges	Junctional release?	Rhomboidal flaps	Steroid?	Poor tissue	ASES score pre-operatively	ASES score postoperatively	OSS pre-operatively	OSS postoperatively
1	Moderate	U-shaped	20	12	No	No	Yes	No	22	83	23	30
2	Large	U-shaped	28	18	Yes	No	No	No	43	83	30	40
3	Moderate	Crescentic	32	22	No	No	No	No	48	90	26	42
4	Moderate	Crescentic	20	14	No	No	Yes	No	41	81	18	44
5	Moderate	U-shaped	16	10	No	No	Yes	No	60	85	27	35
6	Moderate	U-shaped	14	8	No	No	Yes	No	43	55	29	37

For six patients, the mean number of sutures used in repair = 21.6. For six patients, the mean number of sutures bridges used in repair = 14. For the 81 remaining patients, the mean number of total sutures = 19.5. For 81 patients, the mean number of suture bridges = 12.9. OSS, Oxford Shoulder Score; ASES, American Shoulder and Elbow Surgeons.

Postoperatively, pain was relieved at a mean (SD) of 8 (12) weeks and the mean (SD) time of being able to sleep through the night was 4.5 (6.4) weeks. Thirty-seven percent of patients were retired and 4% were long-term unemployed. This left 54% in work at the time of surgery. All of the patients in work returned to work at a mean of 8.3 (6.6) weeks. Ninety-seven percent of the patients were drivers, and all returned to driving at a mean (SD) of 6.6 (4.4) weeks after surgery.

Sixty-eight percent were nonsmokers. Forty-seven percent had contralateral rotator cuff tears of which 36% received surgical management and 64% were undergoing conservative management.

Five patients (6%) reported still having residual stiffness at 1 year, although none wanted a formal release. There were no deep infections, although two (2%) had a minor wound infection that responded immediately to antibiotics. One Capstan screw that had slightly backed out was removed because of local irritation and was found to have a healed repair at 2 years following surgery. There was no single case of deltoid dysfunction or disruption.

## Discussion

The objective of a rotator cuff repair is to create a strong repair that remains structurally intact for a decade, with a low re-tear rate. Arthroscopically, it is suture passage and management that are the difficult parts, not anchor placement or knot tying. Thus, suture passage becomes the limiting factor in repair. Accordingly, a new generation of postloaded anchors was devised that allow the suture passage to be performed first before the suture tails are loaded into the anchor, either directly, or using shuttles that are placed through the anchor during manufacture. However, the maximum number of tails that can be postloaded into an anchor is presently four. Because of the complexity of suture management, many surgeons are still using a maximum of three to four single pre-loaded anchors. With simple suture patterns, this gives a maximum of four suture passes; with double-loaded anchors, this allows eight suture passes; and the maximum possible with double-loaded anchors and mattress sutures is sixteen passes. There are very few surgeons in the world with the dexterity to suture manage sixteen pre-loaded suture tails in the confines of the subacromial space.

It has previously been shown that the strength of repair is directly proportional to the number of suture passages.<sup>28</sup> It is now often the case that the weakest part of the chain is the tendon itself, and therefore as many suture passes placed as widely as possible across as large an area as possible are needed. The Capstan screw technique allows the sutures to be passed first, and then they are tensioned using a round turn on the

smooth shank of the Capstan screw before being tied permanently to it. The mean number of suture passes in this study was 19.7 passes, with a maximum of 37 passes. Biomechanical studies on the Capstan screw technique with the screw placed 2 cm down the lateral cortex of the humerus from the footprint demonstrated no pullout of the capstan screw and suture breakage as the mechanism of failure at a mean of 900 N (range 650 N to 1250 N).<sup>24</sup> In comparison single anchor biomechanically studies have demonstrated mean failures ranging from 380–502 N.<sup>29</sup>

Performing a two-row repair, rather than a one-row repair, allows the load to be spread over a wider area of footprint and is simple to perform at mini-open repair. Recent metanalysis shows that a two-row repair reconstructs the footprint better, is stronger, has less gap formation and improves tensile strength.<sup>30</sup> Taking the tails of the medial row sutures over the cuff and attaching them to the lateral row compresses the tendon onto the footprint. This has been termed the suture-bridge technique and gives additional purchase to the repair.<sup>31</sup> The Capstan screw technique allows suture bridges to be used, with each suture bridge being approximately equivalent to one suture passage. The mean of 19.7 passes and 13 bridges gives an immense equivalent of 32.7 (the maximum of 37 passes and 28 suture bridges gives enormous strength to the tendon suture interface).

Advocates of arthroscopic repair suggest that open repair leads to deltoid disruption, more postoperative pain and a higher rate of infection. However, this present study shows no case of deltoid dysfunction or disruption, and no deep infections. Furthermore, selective studies have demonstrated that flexion and abduction power can be reduced by up to 45% with complete re-tears compared to those with full tendon healing. They also demonstrated that patients' with a re-tear had up to a 40% and 55% less ability to generate shoulder power and withstand a load. Thus, this provides even more incentive to achieve as solid a repair as possible.<sup>21,22</sup>

The present study reports a clinical re-tear rate of 3.4%, an imaged re-tear rate of 6.8%, a satisfaction rate of 91%, an improvement in OSS of 22.7 points ( $p < 0.0001$ ) and an improvement in flexion of 51° ( $p < 0.0001$ ). Such a strong repair has allowed us now to move to a rapid rehabilitation regime with patients returning to work and function much earlier than previously. However, we recognize that only a small number of patients were scanned postoperatively. Thus, the reported re-tear figures above could represent an underestimate and not an absolute accurate percentage of re-tears. However, funding to enable scanning of the whole cohort of patients was not available.

We commend the Capstan screw technique as a simple, rapid, strong mini-open technique, achieving

results as good as any reported in the literature. The next step will be to convert this to a simple, reproducible arthroscopic technique.

### Declaration of conflicting interests

None declared.

### Funding

This research received no specific grant from any funding agency in the public, commercial or not-for-profit sectors.

### References

- Murphy RJ, Maxwell R, Kulkarni R, Beard DJ and Carr AJ. Rates of arthroscopic subacromial decompression and rotator cuff repair surgery in the NHS in England from 2000 to 2010. *Shoulder Elbow* 2011; 3: 258.
- Robinson PM, Roy BR. *Rotator cuff surgery in the UK. Who is doing what?* British Elbow And Shoulder Society 20th Annual Scientific Meeting London, June 2009.
- Slabaugh MA, Nho SJ, Grumet RC, et al. Does the literature confirm superior clinical results in radiographically healed rotator cuffs after rotator cuff repair? *Arthroscopy* 2010; 26: 393–403.
- Ropiak RR, Zmistowski BM and Ciccotti BA. *Postoperative pain after open and arthroscopic rotator cuff repair*. San Diego, CA: Publisher, 2011.
- Adla DN, Rowsell M and Pandey R. Cost-effectiveness of open versus arthroscopic rotator cuff repair. *J Shoulder Elbow Surg* 2010; 19: 258–61.
- El-Azab H, Buchmann S, Beitzel K, Waldt S and Imhoff AB. Clinical and structural evaluation of arthroscopic double-row suture-bridge rotator cuff repair: early results of a novel technique. *Knee Surg Sports Traumatol Arthrosc* 2010; 18: 1730–7.
- Verma NN, Dunn W, Adler RS, et al. All-arthroscopic versus mini-open rotator cuff repair: a retrospective review with minimum 2-year follow-up. *Arthroscopy* 2006; 22: 587–94.
- Millar NL, Wu X, Tantau R, Silverstone E and Murrell GA. Open versus two forms of arthroscopic rotator cuff repair. *Clin Orthop Relat Res* 2009; 467: 966–78.
- Liem D, Bartl C, Lichtenberg S, Magosch P and Habermeyer P. Clinical outcome and tendon integrity of arthroscopic versus mini-open supraspinatus tendon repair: a magnetic resonance imaging-controlled matched-pair analysis. *Arthroscopy* 2007; 23: 514–21.
- Liem D, Lichtenberg S, Magosch P and Habermeyer P. Magnetic resonance imaging of arthroscopic supraspinatus tendon repair. *J Bone Joint Surg Am* 2007; 89: 1770–6.
- Pauly S, Gerhardt C, Chen J and Scheibel M. Single versus double-row repair of the rotator cuff: does double-row repair with improved anatomical and biomechanical characteristics lead to better clinical outcome? *Knee Surg Sports Traumatol Arthrosc* 2010; 18: 1718–29.
- Randelli P, Arrigoni P, Ragone V, Aliprandi A and Cabitza P. Platelet rich plasma in arthroscopic rotator cuff repair: a prospective RCT study, 2-year follow-up. *J Shoulder Elbow Surg* 2011; 20: 518–28.
- Bishop J, Klepps S, Lo IK, Bird J, Gladstone JN and Flatow EL. Cuff integrity after arthroscopic versus open rotator cuff repair: a prospective study. *J Shoulder Elbow Surg* 2006; 15: 290–9.
- Tashjian RZ, Hollins AM, Kim HM, et al. Factors affecting healing rates after arthroscopic double-row rotator cuff repair. *Am J Sports Med* 2010; 38: 2435–42.
- Fuchs B, Gilbert MK, Hodler J and Gerber C. Clinical and structural results of open repair of an isolated one-tendon tear of the rotator cuff. *J Bone Joint Surg Am* 2006; 88: 309–16.
- Klepps S, Bishop J, Lin J, et al. Prospective evaluation of the effect of rotator cuff integrity on the outcome of open rotator cuff repairs. *Am J Sports Med* 2004; 32: 1716–22.
- Lee E, Bishop JY, Braman JP, Langford J, Gelber J and Flatow EL. Outcomes after arthroscopic rotator cuff repairs. *J Shoulder Elbow Surg* 2007; 16: 1–5.
- Gerber C, Fuchs B and Hodler J. The results of repair of massive tears of the rotator cuff. *J Bone Joint Surg Am* 2000; 82: 505–15.
- Galatz LM, Ball CM, Teefey SA, Middleton WD and Yamaguchi K. The outcome and repair integrity of completely arthroscopically repaired large and massive rotator cuff tears. *J Bone Joint Surg Am* 2004; 86: 219–24.
- Zumstein MA, Jost B, Hempel J, Hodler J and Gerber C. The clinical and structural long-term results of open repair of massive tears of the rotator cuff. *J Bone Joint Surg Am* 2008; 90: 2423–31.
- Yoo JC, Ahn JH, Koh KH and Lim KS. Rotator cuff integrity after arthroscopic repair for large tears with less-than-optimal footprint coverage. *Arthroscopy* 2009; 25: 1093–100.
- Lubiatowski P, Kaczmarek P, Dziaoch M, et al. Clinical and biomechanical performance of patients with failed rotator cuff repair. *Int Orthopaed* 2013; 37: 2395–401.
- Lafosse L, Brozka R, Toussaint B and Gobezie R. The outcome and structural integrity of arthroscopic rotator cuff repair with use of the double-row suture anchor technique. *J Bone Joint Surg Am* 2007; 89: 1533–41.
- Keenan J and Bunker T. The Capstan screw – a novel repair technique for rotator cuff repair. *J Bone Joint Surg Br* 2002; 84B(Suppl II): 194e.
- Cofield RH. Subscapular muscle transposition for repair of chronic rotator cuff tears. *Surg Gynecol Obstet* 1982; 154: 667–72.
- Limberg AA. *Mathematical principles of local plastic procedures on the surface of the human body*. Leningrad: Medgiz, 1946.
- Borges AF. The rhombic flap. *Plast Reconstr Surg* 1981; 67: 458–66.
- White CD, Bunker TD and Hooper RM. The strength of suture configurations in arthroscopic rotator cuff repair. *Arthroscopy* 2006; 22: 837–41.

29. Barber F and Herbert MA. Cyclic loading biomechanical analysis of the pullout strengths of rotator cuff and glenoid anchors: 2013 Update. *Arthroscopy* 2013; 29: 832–44.
30. Prasathaporn N, Kuptniratsaikul S and Kongruekreatiyos K. Single-row repair versus double-row repair of full-thickness rotator cuff tears. *Arthroscopy* 2011; 27: 978–85.
31. Park MC, Elattrache NS, Tibone JE, Ahmad CS, Jun BJ and Lee TQ. Part I: footprint contact characteristics for a transosseous-equivalent rotator cuff repair technique compared with a double-row repair technique. *J Shoulder Elbow Surg* 2007; 16: 461–8.